

# Radiography Open

ISSN: 2387-3345

Vol 8, Nr 1 (2022)

<https://doi.org/10.7577/radopen.5113>

## Accessory spleen. A diagnostic challenge

S.S. Celi Simbaña\*<sup>1</sup>, D.S. Andrade Mora<sup>2</sup>, J.E. Mendoza Benalcázar<sup>3</sup>

<sup>1</sup>Ecuadorian Institute of Social Security. I.E.S.S., Center of Médical Specialties "Comité del Pueblo", Teaching and Research Committee of the Center for Specialties "Comité del Pueblo".

<sup>2</sup>Central University of Ecuador, Faculty of Medical Sciences, Medicine School.

<sup>3</sup>Ecuadorian Institute of Social Security. I.E.S.S., Center of Médical Specialties "Comité del Pueblo", General medicine.

\*Corresponding author e-mail address: [ssantiago.celi19@gmail.com](mailto:ssantiago.celi19@gmail.com)

**Keywords:** Accessory Spleen, Diagnostic Imaging, Tomography, X-Ray Computed, Case Study

### Abstract

**Introduction:** Accessory spleen, also called supernumerary spleen, is a generally benign and asymptomatic condition, characterized by the location of splenic tissue outside the spleen.

Its prevalence has been reported between 10% to 30% of the population. **Materials and**

**Methods:** Patient evaluated for recurrent urinary tract infection in which a computed tomography urography without contrast was requested, incidentally finding an accessory spleen.

**Results:** Clinical case report and diagnostic imaging challenge.

**Conclusions:** The accessory spleen is a condition of congenital origin, relatively frequent for which it should be considered in the spectrum of the differential diagnosis of acute abdomen and intra-abdominal masses since its timely diagnosis can avoid unnecessary surgeries.

### Introduction

Accessory spleen, also called supernumerary spleen, is a generally benign and asymptomatic condition, characterized by the location of splenic tissue outside the spleen. Its prevalence has been reported between 10% and 30% of the population.<sup>1</sup>

©2022 the author(s). This is an Open Access article distributed under the terms of the Creative Commons Attribution 4.0 International License (<http://creativecommons.org/licenses/by/4.0/>), allowing third parties to copy and redistribute the material in any medium or format and to remix, transform, and build upon the material for any purpose, even commercially, provided the original work is properly cited and states its license.

Accessory spleen. A diagnostic challenge. Case study.

Ectopic splenic tissue in 80% of cases is found in the splenic hilum, 17% within the pancreatic tail, and the rest within the greater omentum or gastrointestinal tract.<sup>2</sup>

### **Organogenesis of the spleen**

Between 5 and 6 weeks of embryonic development, mesenchymal cells migrate from the midline of the dorsal mesentery to the upper left abdominal quadrant to fuse and form the normal splenic primordium. It is in this period where, due to congenital defects, accessory spleens can be generated, derived from the separation of mesenchymal cells or their lack of fusion.<sup>8</sup>

### **Physiology**

The spleen is made up of red pulp (stroma) and white pulp (parenchyma). It fulfills the function of filtering the blood, exposing it to the white pulp made up of white blood cells, which phagocytize defective erythrocytes, and pathogens such as bacteria, fungi, and viruses, in addition to allowing the maturation of white blood cells.<sup>10</sup> Accessory spleens show the same morphology and physiology, in reduced sizes.<sup>1</sup>

### **Diagnosis**

Supernumerary spleens are diagnosed using imaging techniques such as computed tomography (CT) or magnetic resonance imaging (MRI).<sup>4</sup> Most of the reports consulted agreed on the idea that; For efficient diagnosis of accessory spleens, the use of more than one imaging method is required.

Supernumerary spleens are relevant findings since they constitute diagnostic challenges<sup>7</sup> as they are confused with endometriosis, malignant tumors, reactive lymph nodes or gastrointestinal tumors.<sup>5</sup>

In the differential diagnosis of these findings, splenosis should be considered; It arises from the implantation of splenic tissue outside the spleen due to partial rupture of the same secondary to trauma. This implanted tissue is nourished by local neovascularization and as an outstanding feature, the splenosis lacks its own capsule.<sup>3</sup>

The absence of typical structures differentiates splenosis from the accessory spleen since the latter has all the structures of the normal spleen in reduced size.

Therefore, we point out that the accessory spleen has no anatomical or vascular relationship with the normal spleen, but it does have a physiological function equal to that of the normal spleen.<sup>8</sup>

Serious complications of these supernumerary organs have been reported, such as torsion, which causes acute abdominal pain, ischemia, hemorrhagic shock, peritonitis, and intestinal obstruction.<sup>6</sup> In case of complication, its diagnosis is complicated since the non-specific symptoms and the small size of the lesions mean that most cases of torsion of the accessory spleen are not diagnosed before exploratory surgery<sup>9</sup>, generating unnecessary surgeries.

## Treatment

Being an asymptomatic condition, treatment is conservative in most cases. However, in serious, compressive, and symptomatic injuries, or in cases of torsion, surgery is necessary.

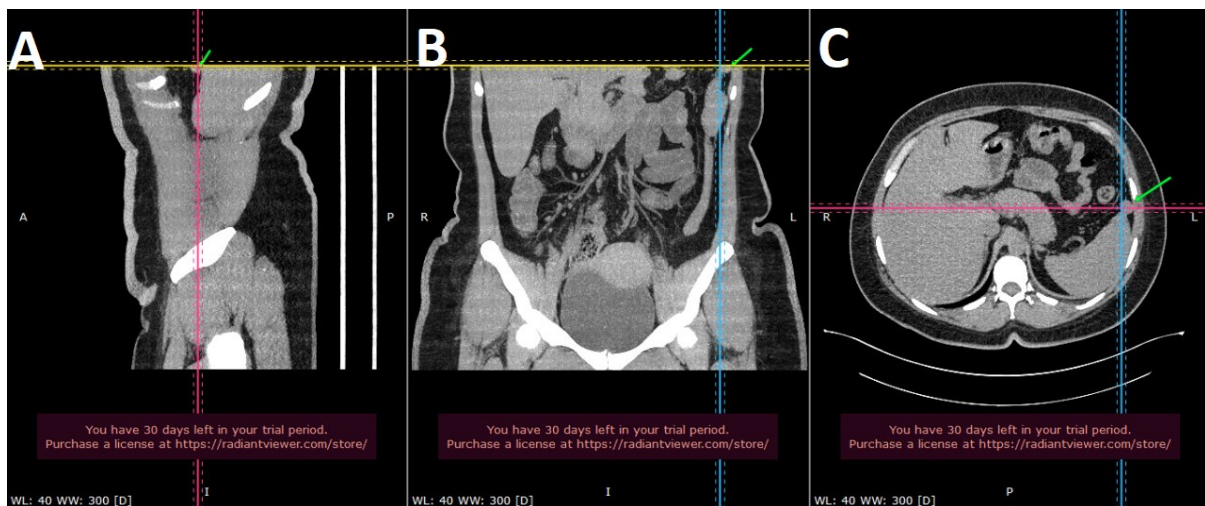
## Clinical case

A 38-year-old female patient, weight: 94kg, height: 164cm, Body Mass Index : 34.9 with a history of: hypothyroidism, high blood pressure, grade 1 obesity according to the WHO obesity classification.<sup>11</sup> She is receiving pharmacological treatment with levothyroxine 100 mcg, enalapril 10mg orally every 12 hours daily. The patient denied a history of abdominal trauma.

Urine tests were performed 30 days before the consultation with results that demonstrated urinary infection, in addition to a blood count performed at the time of the assessment that increased leukocytosis. Both exams argued the infectious process of chronic evolution in the patient.

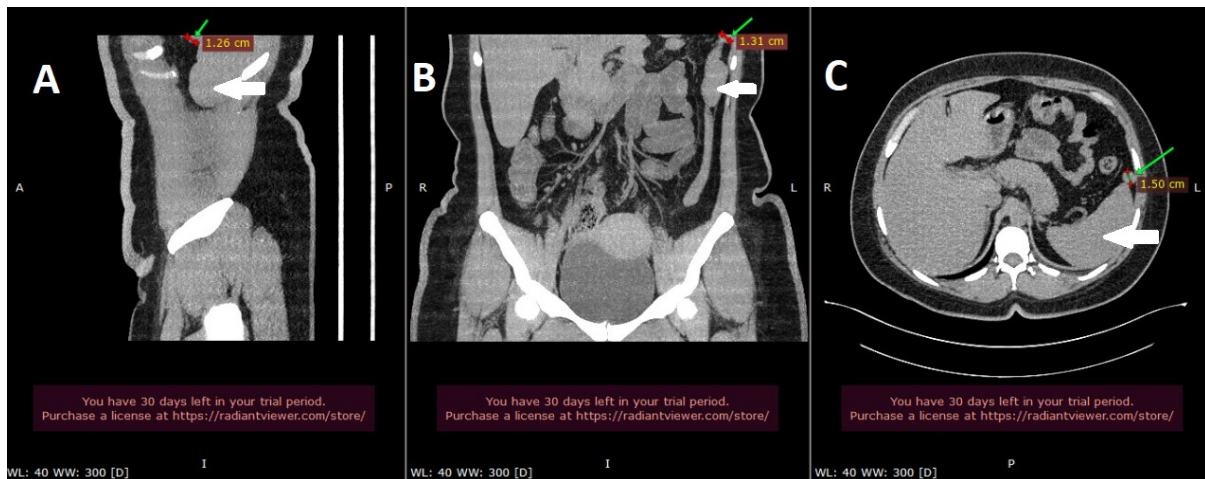
With these antecedents, the presumptive diagnosis was recurrent urinary tract infection and failure of antibiotic therapy. She underwent computed tomography urography without contrast, which reported dilation of the right kidney collecting system and accessory spleen of 15 mm in diameter, in the upper left quadrant of the abdomen, near the cephalic pole of the spleen.

The finding of dilatation of the right renal collecting system explains the chronicity of the infection, considering the possibility of renal lithiasis and intermittent obstruction of the right ureter. No images of renal stones were found.



**Figure 1.**

Abdomen: Computerized axial tomography without contrast. Computed axial tomography urography images, from the same anatomical point (abdomen upper left quadrant, upper pole of the spleen) green date: isodense nodular mass in relation to the spleen. Mass indicated by the intersection of lines. A: Sagittal, B: Coronal and C: Transversal. The multiplanar reconstruction (MPR) option of the program was used, to view medical images: RadiAnt DICOM Viewer (64-bit).



**Figure 2**

Accessory spleen: Computerized axial tomography without contrast. Images part of Urography by computerized axial tomography, of the same anatomical point (abdomen upper left quadrant). White arrow: Spleen. Green arrow: Shows accessory spleen, rounded, isodense in relation to the Spleen, with the following dimensions: A: Sagittal Section 1.26cm in diameter, B: Coronal Section 1.31cm in diameter and C: Transversal Section 1.50cm in diameter. The multiplanar reconstruction (MPR) option of the program was used to view medical images: RadiAnt DICOM Viewer (64-bit).

### Tracing

After diagnosis, the patient was kept under frequent control for comorbidities.

### Patient perspective

The patient received antibiotic treatment guided by antibiogram for her recurrent urinary tract infection and had a satisfactory evolution without recurrence of the infection at 1 year of follow-up.

Once the underlying pathologies are controlled, its long-term prognosis is favorable.

## Discussion

The normal function of the splenic tissue is the phagocytosis of defective and pathogenic erythrocytes, in this sense it could be expected that in the case of the patient these functions are increased generating thrombocytopenia and anemia, however, we find thrombocytosis contradictorily, this finding is secondary to the process urinary infection.<sup>12</sup>

The most important aspect of accessory spleens is timely diagnosis. The reports analyzed coincide with the complexity of identifying the lesions both due to their size and their location<sup>13</sup>, the images of computed tomography, nuclear magnetic resonance and ultrasound are very similar to those found in hypervascular pancreatic tumors.<sup>15</sup>

Definitive diagnosis of accessory spleen by non-invasive methods is a challenge; however, diagnostic efforts would prevent unnecessary surgery.

Accessory spleen. A diagnostic challenge. Case study.

In this sense, combining the different imaging methods and structural study of lesions are key to improving the level of certainty and decision-making.

Remembering that the accessory spleens have their own capsule and vascular system dependent on the splenic artery, therefore, they will be structures that enhance the application of contrasts in equal intensity to the main spleen.

In case of doubt, complementary tests such as somatostatin receptor-based techniques, or single photon emission tomography/scintigraphy with denatured red blood cells or with sulfur colloid, both labeled with technetium 99 (Tc-99m), or invasive procedures such as ultrasound or computed tomography-guided fine-needle aspiration, these techniques may be limited by the size and location of the lesion. A useful strategy in the evaluation of these lesions is to compare the behavior of the mass with the main spleen in the different imaging techniques since they tend to behave in a similar way.<sup>13</sup>

The main weakness of our study is the fact that a contrast-enhanced computed tomography was not performed, since this would not have made it possible to visualize the vascular pedicle of the accessory spleen, in addition to allowing a 3D reconstruction of the images.

## **Conclusion**

Accessory spleen is a relatively common congenital condition, which is why it should be considered in the differential diagnosis of acute abdomen and intra-abdominal masses.

To reach a definitive diagnosis, contrasted diagnostic imaging methods and an adequate structural description are mandatory, in which the presence of differentiated structures of the spleen such as the capsule, vascular pedicle with irrigation dependent on the splenic artery is detailed.<sup>1</sup>

The timely and proper diagnosis of this condition can help avoid incorrect diagnoses and unnecessary surgeries.

## **Ethical considerations**

This work was developed respecting all bioethical principles, anonymity of the patient and prior obtaining informed consent.

## **Conflicts of interest**

The authors declare no conflict of interest for the development of this article.

## **Financing**

Work fully financed by the authors.

## References

1. Ingraham, C., Carter, A. S., Kramer, S., & Pacis, M. (2022). Accessory Spleen and Endometriosis. *Journal of minimally invasive gynecology*, 29(2), 185–186. <https://doi.org/10.1016/j.jmig.2021.10.010>
2. Kato, T., Matsuo, Y., Ueda, G., Aoyama, Y., Omi, K., Hayashi, Y., Imafuji, H., Saito, K., Tsuboi, K., Morimoto, M., Ogawa, R., Takahashi, H., Kato, H., Yoshida, M., Naitoh, I., Hayashi, K., Takahashi, S., & Takiguchi, S. (2020). Epithelial cyst arising in an intrapancreatic accessory spleen: a case report of robotic surgery and review of minimally invasive treatment. *BMC surgery*, 20(1), 263. <https://doi.org/10.1186/s12893-020-00927-0>
3. Zhang, J., Zhong, J. W., Lu, G. R., Zhou, Y. H., Xue, Z. X., & Ye, M. S. (2020). Accessory spleen originating from the intrinsic muscularis of the stomach misdiagnosed as gastrointestinal stromal tumor: a case report. *The Journal of international medical research*, 48(8), 300060520935304. <https://doi.org/10.1177/0300060520935304>
4. Akkaşoğlu, S., Çelebioğlu, E. C., Çalışkan, S. & Sancak, İ. T. (2019). Retrospective radiologic analysis of accessory spleen by computed tomography. *Anatomy*, 13 (2), 87-91. Retrieved from <https://dergipark.org.tr/tr/pub/anatomy/issue/52102/582471>
5. Trujillo, S. G., Saleh, S., Burkholder, R., Shibli, F., & Shah, B. (2022). Accessory Spleen: A Rare and Incidental Finding in the Stomach Wall. *Cureus*, 14(5), e24977. <https://doi.org/10.7759/cureus.24977>
6. Ren, C., Liu, Y., Cao, R., Zhao, T., Chen, D., Yao, L., & Pan, Z. (2017). Colonic obstruction caused by accessory spleen torsion: A rare case report and literature review. *Medicine*, 96(39), e8116. <https://doi.org/10.1097/MD.00000000000008116>
7. Yadav, S. P., Kotak, S. D., Kumar, S., Pujari, V. S., & Chandrasekaran, A. (2020). Intrapancreatic accessory spleen: An imaging enigma. *The Indian journal of radiology & imaging*, 30(3), 392–394. [https://doi.org/10.4103/ijri.IJRI\\_407\\_20](https://doi.org/10.4103/ijri.IJRI_407_20)
8. Chen, G., Nie, L., & Zhang, T. (2021). An extremely rare case of a gastric accessory spleen: case report and review of the literature. *BMC gastroenterology*, 21(1), 275. <https://doi.org/10.1186/s12876-021-01852-z>
9. Yoshida, M., Saida, T., Masuoka, S., Urushibara, A., Chiba, F., & Masumoto, K. (2021). Preoperative Diagnosis of a Torsioned Accessory Spleen. *Journal of medical ultrasound*, 29(2), 116–118. [https://doi.org/10.4103/JMU.JMU\\_35\\_20](https://doi.org/10.4103/JMU.JMU_35_20)
10. Moore, R D., Mumaw, V.R., Schoenberg, M.D. (1964). The structure of the spleen and its functional implications. *Experimental and molecular pathology*, 3, 31–50. [https://doi.org/10.1016/0014-4800\(64\)90016-4](https://doi.org/10.1016/0014-4800(64)90016-4)
11. Weir, C. B., & Jan, A. (2022). BMI Classification Percentile And Cut Off Points. In *StatPearls*. StatPearls Publishing. <https://pubmed.ncbi.nlm.nih.gov/31082114/>
12. Rokkam, Venkata R. and Rajesh Kotagiri. "Secondary Thrombocytosis." *StatPearls*, StatPearls Publishing, 1 August 2022. <https://pubmed.ncbi.nlm.nih.gov/32809645/>
13. Rodríguez Vargas, D., Parada Blázquez, M. J., & Vargas Serrano, B. (2019). Diagnostic imaging of abnormalities in the number and location of the spleen. Diagnóstico por imagen de anomalías en el número y localización del bazo. *Radiología*, 61(1), 26–34. <https://doi.org/10.1016/j.rx.2018.07.002>
14. Beara-Lasic, L., & Goldfarb, D. S. (2020). Nephrolithiasis in women: how different from men?. *Current opinion in nephrology and hypertension*, 29(2), 201–206. <https://doi.org/10.1097/MNH.0000000000000577>
15. Vandekerckhove, E., Ameloot, E., Hoorens, A., De Man, K., Berrevoet, F., & Geboes, K. (2021). Intrapancreatic accessory spleen mimicking pancreatic NET: can unnecessary surgery be avoided?. *Acta clinica Belgica*, 76(6), 492–495. <https://doi.org/10.1080/17843286.2020.176235>